

## CASE STUDY

- 100% WOUND REDUCTION IN 4 WEEKS
- 4 ACTIGRAFT APPLICATIONS

### PATIENT:

20 Year Old, Male

### PAST MEDICAL HISTORY:

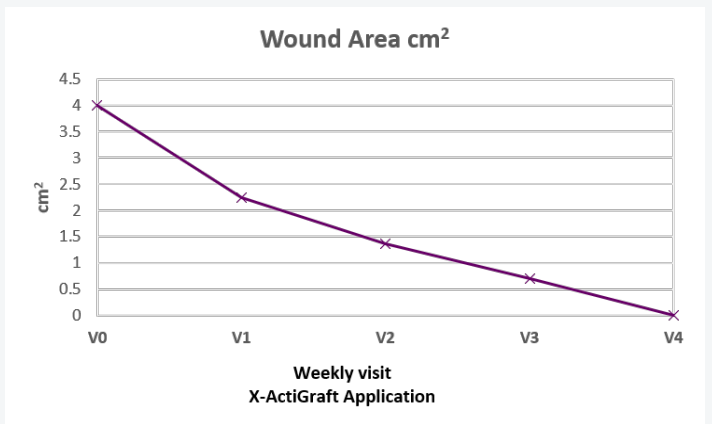
Quadriplegia

### WOUND HISTORY:

- Stage 3-4. 6 month old pressure injury on the ischium

### PAST TREATMENTS:

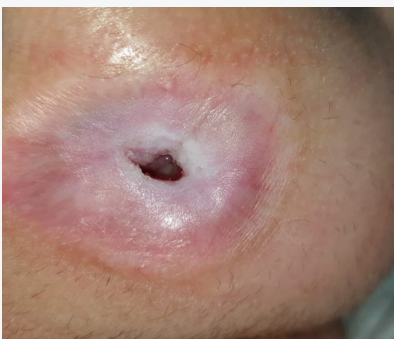Debridement and VAC



V=Weekly Application

### ACTIGRAFT TREATMENT PROGRESSION:

Week 1



Week 4

